

Foetal presentation of long QT syndrome

Chloë THEEUWS¹, MD; Dieter NUYENS², MD, PhD; Marc GEWILLIG³, MD, PhD

¹Dept. of Pediatrics, University Hospitals Leuven, Leuven, Belgium; ²Dept. of Cardiology, University Hospitals Leuven, Leuven, Belgium;

³Dept. of Pediatric Cardiology, University Hospitals Leuven, Leuven, Belgium.

Summary Long-QT syndrome is a rare, inherited cardiac channelopathy that is characterized by arrhythmia, syncope and sudden cardiac death. Foetal symptoms are very rare and prenatal diagnosis is difficult. We report on a foetal presentation of long-QT syndrome with severe hydrops and a chaotic heart rhythm at 32 weeks of gestation. Postnatal electrocardiography showed runs of polymorphic ventricular tachycardia and an extremely prolonged-QT segment (QTc of 640 ms). The initial approach of overdrive pacing, followed by the combined therapy of a beta blocker, a sodium channel blocker (mexiletine) and potassium supplementation proved successful in maintaining a stable sinus rhythm. The girl was doing well at eight months of follow-up. In this patient a timely diagnosis and effective management after birth have been life-saving. The intrauterine manifestation of foetal atrioventricular dissociation and ventricular arrhythmia should raise suspicion of congenital long-QT syndrome.

Keywords Foetal long-QT syndrome – ventricular tachycardia – hydrops foetalis – cardiac pacing – mexiletine.

INTRODUCTION

Long-QT syndrome (LQTS) is a rare (1:2500)¹, inherited disorder that is characterized by cardiac arrhythmia, syncope and sudden cardiac death. It is associated with delayed repolarization of ventricular cells, detected as abnormally long-QTc intervals on the electrocardiogram (ECG). LQTS is a congenital channelopathy caused by mutations in genes coding for cardiac ion channel subunits or channel associated proteins. To date, 12 different genes are known in which several mutations are described. Genotype-specific clinical features, risk stratification and management are associated with distinct LQTS variants². Foetal symptoms are very rare and prenatal diagnosis is difficult. Its manifestation during the perinatal period is associated with a high cardiac risk³. We report on a foetal presentation of LQTS with a chaotic ventricular rhythm and severe hydrops.

CASE REPORT

A 28-year-old pregnant Moroccan woman, G3P2A0, at 32 weeks of gestation, was referred to our centre because of polyhydramnion, hydrops foetalis and chaotic foetal heart rhythm. Ultrasounds performed earlier in pregnancy up to 20 weeks were normal. At 32 weeks of gestation the woman experienced abdominal pain and less foetal movements. Polyhydramnion and hydrops foetalis (severe skin oedema, hydrothorax and ascites) were noted on ultrasound. On foetal echocardiography an irregular, fast heart rhythm with atrioventricular dissociation and peripheral deficit was seen. An urgent caesarian section was performed to deliver the 3000 g female baby (estimated dry weight of 1800 g). Immediate neonatal care included endotracheal intubation and ventilation, placement of a venous umbilical catheter, left chest drain and peritoneal drain. Cardiac monitoring showed sinus tachycardia (± 180 bpm) immediately after birth; the QT segment was difficult to assess. Echocardiography showed a morphologically and functionally normal heart. A few hours after birth, as the heart rate gradually diminished to about 145 bpm, tachyarrhythmias developed. A chaotic heart rhythm with frequent ventricular extrasystoles, runs of ventricular tachycardia (VT) with torsade de pointes and low cardiac output occurred (figure 1, A and B). Serum electrolytes were normal. The very rare episodes of sinus rhythm

Address for correspondence:

Marc Gewillig, MD, PhD, Department of Pediatric Cardiology, University Hospitals Leuven, Herestraat 49, B-3000 Leuven, Belgium.
E-mail: marc.gewillig@uzleuven.be

Received 19 March 2013; accepted for publication 2 April 2013.

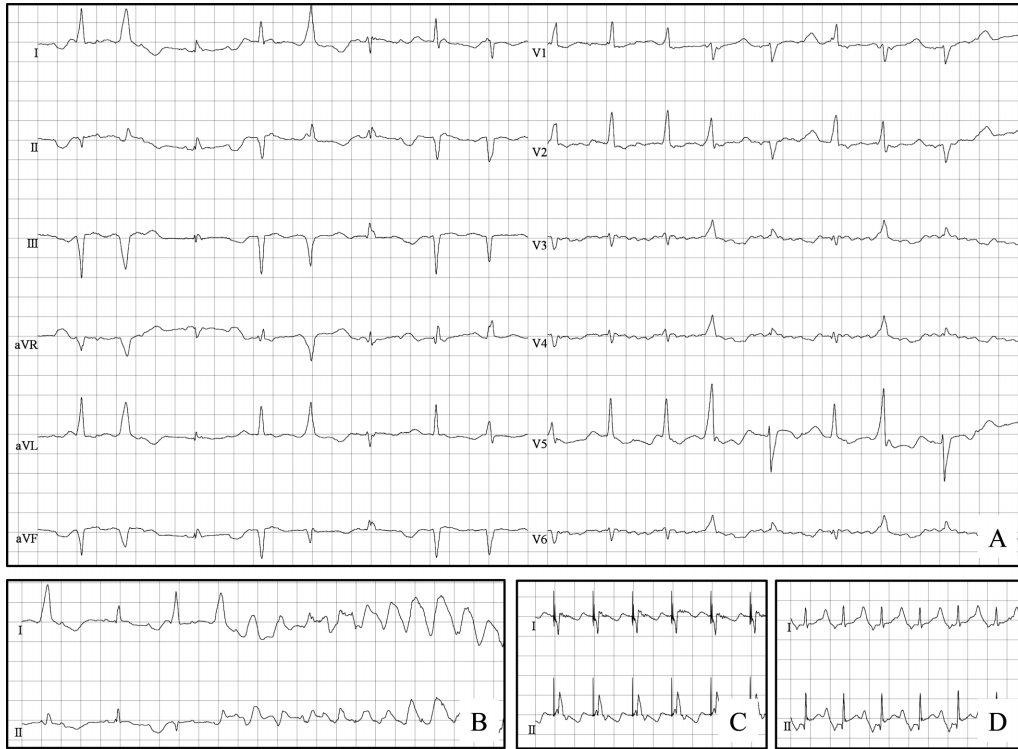


Fig. 1 Electrocardiogram (25 mm/s, 10 mm/mV). Day 1: extreme QT prolongation ($QTc = 640$ ms) and ventricular ectopy; no two consecutive sinus beats were present (panel A); induction of torsades de pointes polymorphic ventricular tachycardia by ventricular extrasystoles (panel B). Day 7: a stable paced rhythm (150 bpm) after placement of the ventricular epicardial pacing wires (panel C). Day 58: a stable sinus rhythm (134 bpm) after removal of the pacing wires, under the combined therapy of propranolol, mexiletine and potassium supplementation. QT prolongation persists ($QTc = 510$ ms) (panel D).

showed an extremely prolonged QT segment with a QTc of 640 ms. Sequential drug trials were performed. On day 1 amiodarone (3 mg/kg/dose) was started. Bradycardia developed and arrhythmias persisted. Quinidine (0.05 mg/kg/min) and potassium supplementation were added without effect. Both amiodarone and quinidine were stopped. On day 2 isoproterenol (0.1 mcg/kg/min) was started to obtain sinus tachycardia. The heart rhythm improved to a predominantly sinus rhythm with some runs of VT. However, a metabolic acidosis gradually developed and isoproterenol had to be stopped. As a higher heart rate seemed to be protective against VT, temporary ventricular epicardial pacing wires were placed on day 2 (figure 2). A stable paced rhythm was achieved while pacing above 150 bpm (figure 1, C). At lower pacing rates ventricular ectopy and torsades de pointes reoccurred. High-rate pacing was maintained in order to improve the haemodynamic condition, allowing the girl to recover from the hydrops. On day 11, propranolol (2 mg/kg/day) and calcium and magnesium supplementation were started. Pacing rate could be gradually

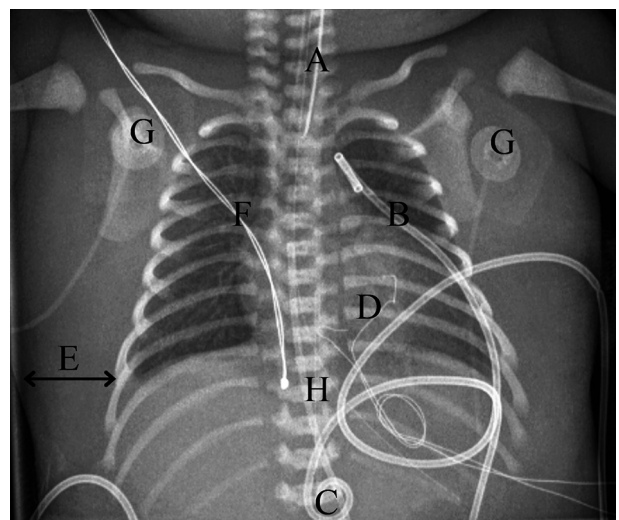


Fig. 2 Chest X ray after placement of the temporary epicardial pacing wires. Note the severe skin oedema. (A) Endotracheal tube, (B) left pleural drain, (C) peritoneal drain, (D) ventricular epicardial pacing wires, placed on the right ventricular anterior wall, (E) skin oedema, (F) external temperature probe, (G) ECG electrode, (H) arterial umbilical catheter.

lowered. On day 13, ventricular arrhythmia reoccurred. Only a combination of drug therapy, electrolyte supplementation and elevating the pacing rate could restore a stable paced rhythm. On day 14, mexiletine (12 mg/kg/day) was started (off-label use): a stable paced rhythm without ventricular ectopy, and shortening of the QTc were seen. While lowering the pacing rate under the combined therapy of propranolol, mexiletine and electrolyte (magnesium, calcium and potassium) supplementation, a stable sinus rhythm was achieved and maintained. On day 16, propranolol was switched to atenolol (0.5 mg/kg/day). Epicardial pacing wires were removed on day 51. Heart rhythm remained stable (figure 1, D). Electrolyte supplementation was sequentially weaned. Magnesium and calcium were stopped without any arrhythmic events. After stopping the potassium supplementation ventricular extrasystoles reoccurred. Potassium supplementation was restarted (3 mEq/kg/day) maintaining a potassium serum level of 4-4.5 mEq/L.

The girl gradually recovered from the hydrops due to the improvement in haemodynamic condition and the administration of plasma, human albumin, intravenous immunoglobulins, diuretics and corticosteroids. Respiratory support was needed until day 53 (endotracheal intubation and ventilation until day 40, nasal continuous positive airway pressure until day 53). Her lowest weight measured was 1,980 g on day 43. The girl could be discharged from hospital on day 82, weighing 3,140 g. Neurological screening (transfontanellar ultrasound, electroencephalogram) and ophthalmologic testing at discharge showed no abnormalities. There was an abnormal brainstem evoked response audiometry (BERA) of the left ear, which persisted at the age of 3 months. Follow-up is scheduled. Treatment at discharge consisted of atenolol, mexiletine and potassium supplementation. At the age of eight months, the patient was doing well on the same medication. ECG showed persistence of QT prolongation with a QTc of 490 ms.

The girl's pedigree had no family history suggestive of LQTS. Familial screening showed a normal ECG in the non-consanguineous Moroccan parents, and the brother and sister.

Genetic testing with the '180k Cytosure ISCA v2 array' (Oxford Gene Technology) was normal. Mutation investigation of the LQT genes showed no mutation in the *KCNE1*, *KCNE2*, *KCNQ1* and *KCNH2* genes. Further genetic testing is pending.

DISCUSSION

Congenital LQTS appears to be a silent killer in newborns, accounting for a small portion of sudden infant death syndrome (SIDS) cases. Mutations in arrhythmia

susceptibility genes are found in up to 10% of autopsy-negative SIDS victims⁴. The sinus tachycardia that is normally present in newborns seems to stabilize heart rhythm temporarily. As heart rate decreases in the growing infant, malignant arrhythmias may develop.

Foetal presentation of congenital LQTS is very rare and prenatal diagnosis is difficult. There is no family history in 30% of cases⁴. Its manifestation during the perinatal period is associated with a high cardiac risk and a malignant clinical course³. Foetal arrhythmias may cause a reduction in systemic and umbilical blood flow leading to hydrops foetalis. Postnatal ECG still is the gold standard for the diagnosis of LQTS⁵. However, QTc can be difficult to estimate during sinus tachycardia immediately after birth, as it was in our case.

Early-onset LQTS should be treated with the combination of beta blockers and sodium channel blockers⁶. Beta blockers are the first choice of therapy in patients with congenital LQTS. They reduce the incidence of syncope and sudden cardiac death, especially in LQT1 patients. They are less effective in LQT2 patients⁷. In LQT3 patients their use is controversial, as adrenergic agonists are known to be anti-arrhythmic in LQT3 mouse models⁸. Sodium channel blockers such as mexiletine (class 1B anti-arrhythmic) have been proposed as gene-specific therapeutic agents in LQT3 syndrome³. In the LQT3 syndrome a gain of function mutation in the voltage-gated cardiac sodium channel causes an increase in excitatory membrane current⁹. Sodium channel blockers selectively suppress increased persistent current conducted by mutant channels and may normalize ventricular repolarization and shorten the QTc interval in LQT3^{9,10}. However, experimental data indicate that mexiletine may also be effective in suppressing the development of torsade de pointe in LQT2 and LQT1 syndrome. It should be used at the moment in the presence of beta blockers or under the backup of an implantable cardioverter/defibrillator (ICD) even in LQT3 patients⁷.

In our case an extremely prolonged repolarization (QTc 640 ms) was seen. The combined therapy of atenolol, mexiletine and potassium supplementation proved successful in maintaining sinus rhythm. An increase in the extracellular concentration of potassium is thought to be beneficial by enhancing the repolarizing K⁺ currents⁹. Mexiletine is not available in Europe and had to be requested as a transatlantic delivery. After starting mexiletine, QTc shortening was seen, but QT prolongation persisted with a QTc of 520 ms at discharge and of 490 ms at the eight months follow-up. Lifelong follow-up and drug therapy will be necessary as QT prolongation and associated risks will persist. Most likely an implantable cardioverter/defibrillator (ICD) will be required, but optimal timing for placement needs to be determined.

As early clinical presentation of LQTS is very rare, long-term prognosis of these symptomatic infants is largely unknown. Horigome et al.⁶ performed a nationwide questionnaire survey study in Japan to investigate the clinical characteristics and genetic background of congenital LQTS diagnosed in foetal, neonatal and infantile life. A total of 58 cases were investigated. During the follow-up period of 8 days to 23.5 years (median 4.25 years) 7 sudden cardiac deaths and 7 aborted cardiac arrests were registered. Among these 14 cases, 12 had been under pharmacotherapy, 5 with both beta blockers and sodium channel blockers, and 2 had pacemaker or implantable cardioverter/defibrillators.

In conclusion, foetal presentation of LQTS is very rare, but it is associated with a high cardiac risk. The intrauterine manifestation of foetal atrioventricular dissociation and ventricular arrhythmia should raise suspicion of congenital LQTS. Prompt diagnosis and effective management after birth are necessary and possibly life-saving. In our case overdrive pacing was useful in stabilizing heart rhythm in the acute setting and mexiletine proved successful in shortening QTc and decreasing ventricular ectopy.

CONFLICT OF INTEREST: none declared.

REFERENCES

- Schwartz P, Stramba-Badiale M, Crotti L, Pedrazzini M, Besana A, Bosi G, Gabbarini F, Goulene K, Insolia R, Mannarino S, Mosca F, Nespoli L, Rimini A, Rosati E, Salice P, Spazzolini C. Prevalence of the congenital long-QT syndrome. *Circulation* 2009; **120**: 1761-7.
- Lu J, Kass R. Recent progress in congenital QT syndrome. *Curr Opin Cardiol* 2010; **25**: 216-21.
- Schulze-Bahr E, Fenge H, Eitzrodt D, Haverkamp W, Mönnig G, Wedekind H, Breithardt G, Kehl H-G. Long QT syndrome and life threatening arrhythmia in a newborn: molecular diagnosis and treatment response. *Heart* 2004; **90**: 13-6.
- Baruteau A-E, Baruteau J, Joomye R, Martins R, Treguer F, Baruteau R, Daubert J-C, Mabo P, Roussey M. Role of congenital long-QT syndrome in unexplained sudden infant death: proposal for an electrocardiographic screening in relatives. *Eur J Pediatr* 2009; **168**: 771-7.
- Anuwutnavin S, Wanitpongpan P, Chungsomprasong P, Soongswang J, Srisantiroj N, Wataganara T. Fetal long QT syndrome manifested as atrioventricular block and ventricular tachycardia: a case report and a review of the literature. *Pediatr Cardiol* 2012 (Epub ahead of print). Doi:10.1007/s0024601205071.
- Horigome H, Nagashima M, Sumitomo N, Yoshinaga M, Ushinohama H, Iwamoto M, Shiono J, Ichihashi K, Hasegawa S, Yoshikawa T, Matsunaga T, Goto H, Waki K, Arima M, Takasugi H, Tanaka Y, Tauchi N, Ikoma M, Inamura N, Takahashi H, Shimizu W, Horie M. Clinical characteristics and genetic background of congenital long-QT syndrome diagnosed in fetal, neonatal, and infantile life. *Circ Arrhythm Electrophysiol* 2010; **3**: 10-7.
- Shimluzil W, Takeshi A, Antzelevitch C. Specific therapy based on the genotype and cellular mechanism in inherited cardiac arrhythmias. Long QT syndrome and Brugada syndrome. *Curr Pharm Des* 2005; **11**: 1561-72.
- Nuyens D, Stengl M, Dugarmaa S, Rossenbacker T, Compennolle V, Rudy Y, Smits J, Flameng W, Clancy C, Moons L, Vos M, Dewerchin M, Benndorf K, Collen D, Carmeliet E, Carmeliet P. Abrupt rate accelerations or premature beats cause life-threatening arrhythmias in mice with long-QT3 syndrome. *Nat Med* 2001; **7**: 1021-7.
- Priori S, Bloise R, Crotti L. The long QT syndrome. *Europace* 2001; **3**: 16-27.
- Wang D, Crotti L, Shimizu W, Pedrazzini M, Cantu F, De Filippo P, Kishiki K, Miyazaki A, Ikeda T, Schwartz P, George A. Malignant perinatal variant of long-QT syndrome caused by a profoundly dysfunctional cardiac sodium channel. *Circ Arrhythmia Electrophysiol* 2008; **1**: 370-8.